

THE ASCITES SYNDROME IN MEAT-TYPE CHICKENS

A Continuing Education Program Prepared

By RJ Julian

Ontario Veterinary College
University of Guelph, Guelph, Ontario, Canada

In Cooperation with the
Continuing Education Committee
of

The American Association of Avian Pathologists

THE ASCITES SYNDROME IN MEAT-TYPE CHICKENS

Abbreviations Used:

AS:	ascites syndrome	PHS:	pulmonary hypertension syndrome
AV:	atrioventricular	RBC:	red blood cell(s)
CO:	cardiac output	RA:	right atria
DDx:	differential diagnosis	RV:	right ventricle
Hb:	hemoglobin	RVF:	right ventricular failure
H-P:	hepato-peritoneal	RVH:	right ventricular hypertrophy
LV:	left ventricle	SaO ₂	Hb oxygen saturation
MR:	metabolic rate	SDS	sudden death syndrome
PCV:	packed cell volume	VI	valvular insufficiency
PH:	pulmonary hypertension		

Introduction

Ascites is not a disease, it is a sign or lesion that may result from one or more of four physiologic changes that cause an increased production or decreased removal of peritoneal lymph. Ascites syndrome (AS) is assumed to be the same as pulmonary hypertension syndrome (PHS); that is, ascites resulting from pulmonary hypertension-induced right ventricular failure (RVF). Pulmonary hypertension (PH) is caused by increased blood flow or increased resistance to blood flow in the lung. PH causes a pressure overload on the right ventricle (RV), right ventricular hypertrophy (RVH), valvular insufficiency (VI), increased portal pressure, a volume overload on the right ventricle, right ventricular dilation, RVF and ascites. RVF in spontaneous turkey cardiomyopathy (the major cause of ascites in turkey poults) is not the result of PH (Julian 8,9,10).

The anatomy and physiology of the avian respiratory system are important in the susceptibility of meat-type chickens to the AS. The small stature of the modern meat-type chicken, the large, heavy breast mass, the pressure from abdominal contents on air sacs, and the small lung volume, may all be involved in the increased incidence of PHS. Chickens have a thicker respiratory membrane than other birds, and broilers have a thicker respiratory membrane than leghorn-type fowl, so the ability of broilers to move oxygen into hemoglobin (Hb) may not be as good as in other birds. Research on Hb oxygen saturation (SaO₂) in meat-type chickens indicates that fast-growing broilers have a lower % SaO₂ than slow-growing broilers (12). These results suggest that some meat-type chickens are not fully oxygenating their Hb even at low altitude. Increased blood flow, to supply the oxygen required for metabolism in fast-growing meat-type chickens, causes an increase in the blood pressure required to push the blood through the blood capillaries in the lung (pulmonary hypertension). This increase in work-load for the right side of the heart results in sporadic cases of RVF and ascites.

Ascites caused by VI and RVF following RVH and dilation from PH in poultry at high altitude has been recognized for many years (1,2,5,6,16,17). The AS has become prominent in many countries since the early 1980's. The primary cause is the increasingly rapid growth in young meat-type chickens over the past 40 years. However a variety of secondary factors that increase metabolic rate (MR), oxygen requirement or heat production (which raise blood flow and cardiac output), or that increase resistance to blood flow in the lung, can markedly increase the incidence of ascites (Fig. 1) (7,8).

Ascites caused by PH is a production-related disease at low altitude. It can be prevented easily by restricting growth rate. It is possible that some meat-type chickens of the phenotype we have created have reached the limit of blood flow through their lungs and that future improvements in growth rate will only be possible if the lung and abdominal cavity capacities are enlarged. AS at moderate (above 750 m) and high altitude is a much more severe problem because of the polycythemia (resistance to flow) induced by hypoxia (9,26) but it too can be reduced by restricting growth rate (reducing oxygen requirement) (5,22).

Slide 1 Broiler that died from AS following RVF. Note congestion of the skin and enlarged abdomen. At necropsy there would have been ascitic fluid and clots of fibrin in the ventral hepatoperitoneal (H-P) spaces. This broiler would have been sick for several days before it died.

Slide 2 Broiler that died from AS following RVF. This broiler was frozen before the skin was removed to show large accumulation of fluid in the ventral H-P spaces. There is also fluid in the right dorsal H-P space (the triangular section on the anterior part of the yellow frozen material, on left side on the slide). There is very little fluid in the abdominal peritoneal space (visible at the posterior abdomen).

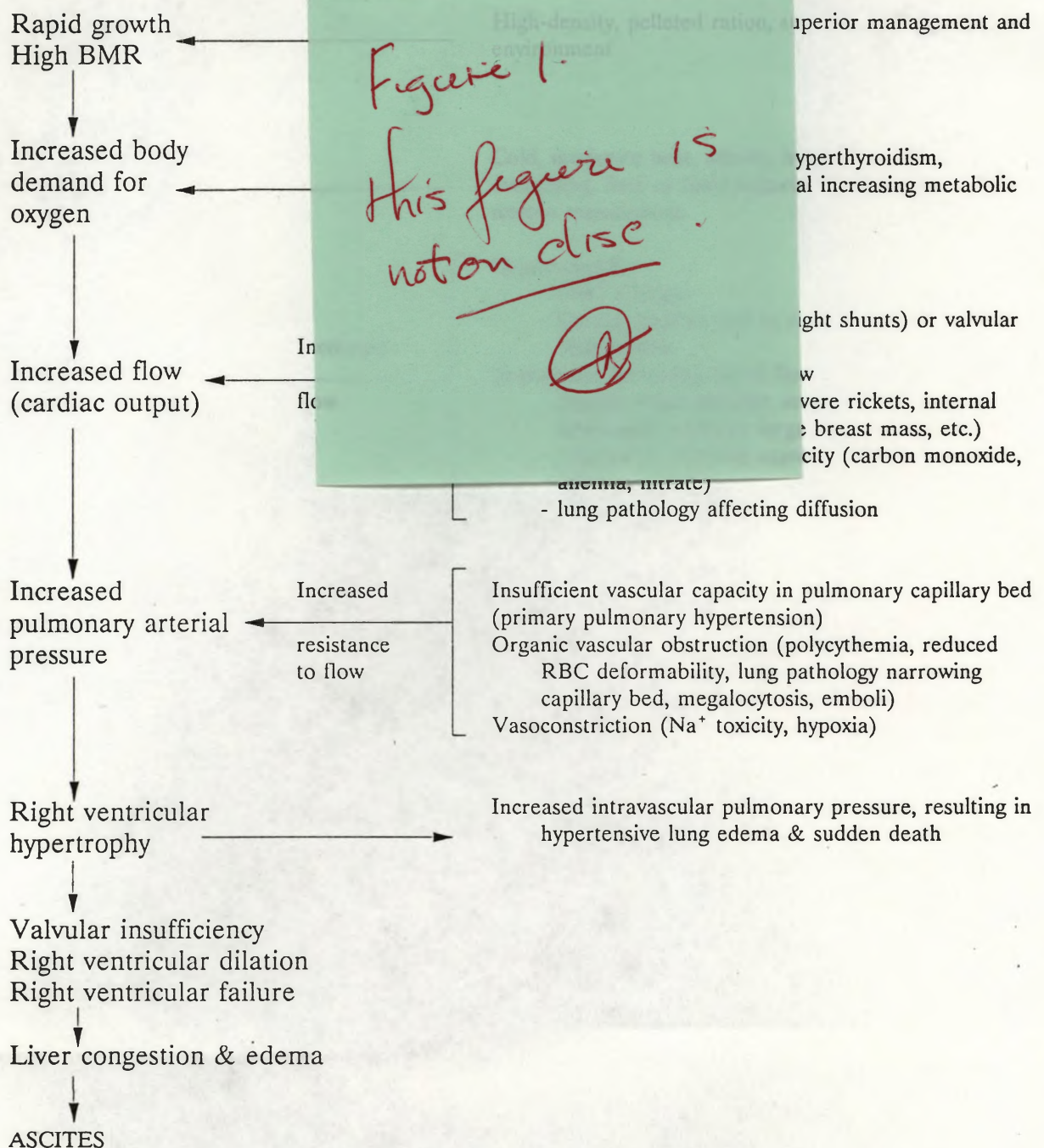
Slide 3 Two broilers that died from AS with less evidence of RVF. These broilers have VI as shown by the swollen, congested liver with a lobular pattern. The RA, sinus venosus and portal vein are dilated. There was little fluid in the H-P spaces, but some fibrin is present on the liver. There is hydropericardium. There is enlargement of the heart and marked RVH. These broilers are in good body condition and have food in the digestive tract. The DDX would be SDS.

These broilers probably died suddenly from lung edema because of high intrapulmonary pressure forcing fluid into the lung tissue.

Slide 4 Hearts viewed from the dorsal (posterior) side and base of the heart (atria removed) from 3 broilers with AS. Normal above. Note enlargement of the RV and AV opening. The AV valve is visible through the opening in the 2 hearts on the left.

Slide 5 Broiler hearts cut in cross section. Normal hearts on right. The hearts in the centre are

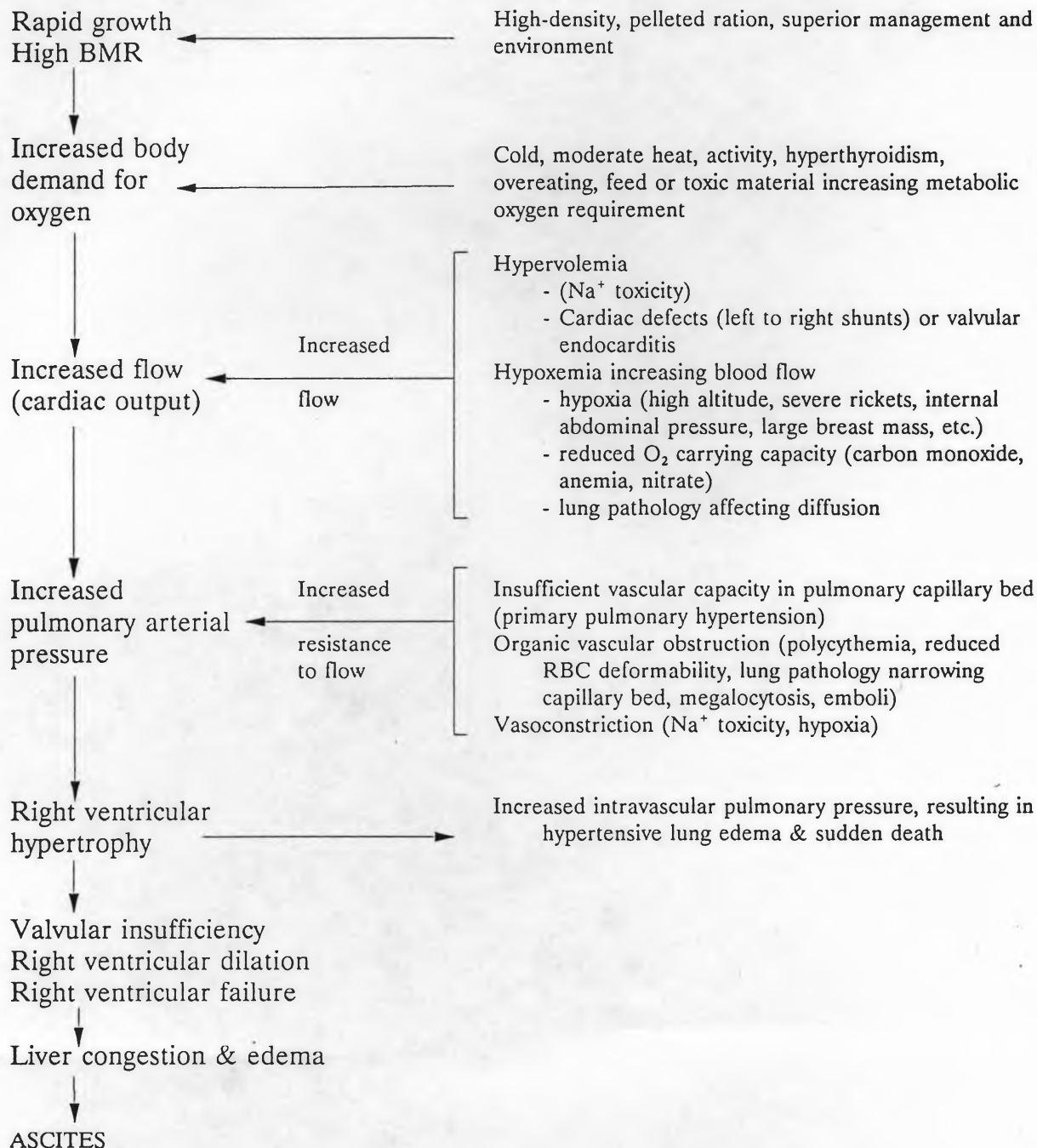
DIAGRAMMATIC SUMMARY OF POSSIBLE CAUSES OF INCREASED PULMONARY ARTERIAL PRESSURE IN BROILER CHICKENS RESULTING IN INCREASED RIGHT VENTRICULAR WORK-LOAD



Adapted from:

Julian, R.J. The effect of increased sodium in the drinking water on right ventricular hypertrophy, right ventricular failure and ascites in broiler chickens. *Avian Pathology* 16: 61-71, 1987.

DIAGRAMMATIC SUMMARY OF POSSIBLE CAUSES OF INCREASED PULMONARY ARTERIAL PRESSURE IN BROILER CHICKENS RESULTING IN INCREASED RIGHT VENTRICULAR WORK-LOAD



Adapted from:

Julian, R.J. The effect of increased sodium in the drinking water on right ventricular hypertrophy, right ventricular failure and ascites in broiler chickens. *Avian Pathology* 16: 61-71, 1987.

from broilers which died with little evidence of RVF (except for 2nd from top showing marked congestion). They have marked RVH but little RV dilation. The hearts on the left are from broilers that died from RVF. The necropsy would have shown all of the lesions associated with RVF, including ascites. The RV is markedly dilated because of the volume overload caused by VI. There is prominent thinning of the LV wall. This is caused by avascular necrosis of myocytes the result of the hypoxemia associated with RVF and the reduced work load on the LV because of VI and reduced CO.

Slide 6

Two broilers that died from AS. There is very slight ascites in the broiler on the left (yellow fluid over intestines) and mild hydropericardium. The heart is enlarged with RVH and RV dilation. There is no ascitic fluid in the broiler on the right. There is a nodular pattern on the liver in both broilers from back-up of venous blood because of VI. The dilated sinus venosus can be seen between the heart and liver in the broiler on the left. The DDX might be hepatitis, but RVH indicates that PH is the cause of the VI and liver damage.

Slide 7

Broiler that died from AS and RVF with large quantity of ascitic fluid and fibrin in the ventral H-P spaces. Enlargement of the RV is obvious. All of the lesions of RVF were present (ascites, fibrin, cyanosis, prominent veins etc.) The DDX might be septicemia with peritonitis. Much of the literature on the AS describes only the lesions which result from RVF (which this broiler shows and which are the same regardless of the cause of the RVF) without mentioning that the cause is pulmonary hypertension resulting in RVH and VI (28).

Slide 8

Two broilers that died from AS and RVF showing the large quantity of clotted protein (fibrin) than can accumulate in the ventral H-P cavities. The more liquid portion of the plasma can return to the vena cava via the lymphatics until venous pressure (the result of RVF) becomes too high.

Slide 9

Broiler that died from AS and RVF. This broiler survived 2-3 wks and there has been chronic, hypoxic liver damage with necrosis and fibrosis leading to atrophy of the liver. The liver capsule is thickened by fibrosis. There was a large quantity of ascitic fluid and marked cyanosis from passive congestion. Note prominent sinus venosus and RA. The DDX might be hepatitis, but in this case the heart lesion caused by PH resulted in the liver disease. In some countries, these changes are erroneously blamed on mycotoxins.

Why broiler chickens are so susceptible to PH and RVF

Slide 10

Low power cross-section of broiler lung showing parabronchiolar lobules and parabronchi. The lung of birds is quite different to mammals. Breathing and blood flow through the lung are also different. Respiration in birds is not controlled by a

diaphragm and the lungs do not expand and contract to move air across the respiratory membrane. Birds breath using abdominal movement and air sacs to draw air through the parabronchi where it diffuses through air capillaries. The lung is small and firm. The blood capillaries are small and form a rather rigid network. The blood capillaries cannot expand to accept increased blood flow above their normal capacity (25). The RBC must curl to pass through the blood capillaries. Increased blood flow or viscosity result in PH and high workload on the RV (19,20,23).

Slide 11

A single lung lobule with parabronchus in the centre. Air leads from the parabronchus to the exchange capillaries. Blood from the right ventricle comes in at the periphery of the lobule. Leaves via vessels around the parabronchus close to the periphery.

Slide 12 & 13

Histologic section of the lung (Fig. 1, slide 13 with an EM slide of my own - work of air de 13 EM blood-gas :553-562. d require ng.

Slide 14

Broiler hearts cut lengthways
Hearts from broilers that died
a broiler that did not have asc
dilation and RA dilation.

The RV of birds is thin-walled indicating that it is a volume pump, not a pressure pump. It responds very rapidly to increase pressure load by hypertrophy and to increased volume load by dilation as does all heart muscle. Note that the right AV valve is a muscle flap and is a continuation of the RV wall. When the RV wall hypertrophies the valve also hypertrophies resulting in leakage and leading to VI.

Heart disease is not the cause of PH-induced ascites, as some people want to believe. The cause of PH-induced ascites (the AS or PHS) is in the lung. The RV is simply responding to the increased work load of PH. The heart can be the cause of ascites when there is primary cardiomyopathy or heart disease caused by atrial or ventricular septal defects, valvular endocarditis or myocarditis (8,10).

Slide 15

Broiler hearts cut in cross-section at the level of the right AV valve free edge. Normal above. Note marked RVH and dilation in the 3 hearts below. The broilers were in RVF and were euthanized and bled out (the hearts are less cyanotic). Note thickened right AV valve. There is thinning of the LV wall, most prominent on the left. This is the result of hypoxemia and reduced CO following RVF.

diaphragm and the lungs do not expand and contract to move air across the respiratory membrane. Birds breathe using abdominal movement and air sacs to draw air through the parabronchi where it diffuses through air capillaries. The lung is small and firm. The blood capillaries are small and form a rather rigid network. The blood capillaries cannot expand to accept increased blood flow above their normal capacity (25). The RBC must curl to pass through the blood capillaries. Increased blood flow or viscosity result in PH and high workload on the RV (19,20,23).

Slide 11

A single lung lobule with parabronchus in the centre. Atria lead out from the parabronchus to the exchange tissue of blood and air capillaries. Blood from the right ventricle comes in at the perimeter and oxygenated blood leaves via vessels around the parabronchus close to the parabronchiolar smooth muscle.

Slide 12 & 13

Histologic section of the lung exchange tissue (H & E x 500), a rigid network of air and blood capillaries. The blood capillaries are smaller than the RBC (slide 13 EM section). Maina, J.N. and King, A.S. (1982). The thickness of the avian blood-gas barrier: qualitative and quantitative observations. *Journal of Anatomy*, 134:553-562. Increased blood viscosity (polycythemia) and/or increased flow would require increased pressure to push the blood through the capillary system in the lung.

Slide 14

Broiler hearts cut lengthways to show valves and wall thickness. Normal heart above. Hearts from broilers that died from AS below. The heart on the left (below) was from a broiler that did not have ascites but shows RVH. The other hearts show RVH, RV dilation and RA dilation.

The RV of birds is thin-walled indicating that it is a volume pump, not a pressure pump. It responds very rapidly to increase pressure load by hypertrophy and to increased volume load by dilation as does all heart muscle. Note that the right AV valve is a muscle flap and is a continuation of the RV wall. When the RV wall hypertrophies the valve also hypertrophies resulting in leakage and leading to VI.

Heart disease is not the cause of PH-induced ascites, as some people want to believe. The cause of PH-induced ascites (the AS or PHS) is in the lung. The RV is simply responding to the increased work load of PH. The heart can be the cause of ascites when there is primary cardiomyopathy or heart disease caused by atrial or ventricular septal defects, valvular endocarditis or myocarditis (8,10).

Slide 15

Broiler hearts cut in cross-section at the level of the right AV valve free edge. Normal above. Note marked RVH and dilation in the 3 hearts below. The broilers were in RVF and were euthanized and bled out (the hearts are less cyanotic). Note thickened right AV valve. There is thinning of the LV wall, most prominent on the left. This is the result of hypoxemia and reduced CO following RVF.

Slide 16

Broiler hearts cut in cross section and with RV removed. These hearts are from 6 wk-old broilers from an ascites research flock. They were collected at processing for RV:TV ratio. Normal above. The 4 broilers (below) had mild to severe ascites. Note marked hypertrophy of RV on right side and marked dilation of RV on left.

Slide 17

RV wall of broiler chickens. Normal on left from SDS broiler. The 6 enlarged RV were from broilers that died from AS. Broilers that die from AS would be expected to have a RV:TV ratio above 0.29, and all 6 were above 0.29. Normal would be 0.21 ± 0.3 . The 3 on the right did not have ascites. Many broilers may have some RVH at processing because of mild PH. They do not develop significant cyanosis or ascitic fluid until the right AV valve fails.

Note endocardiosis on the free edge of the AV valve of enlarged RV. This is a result of stretching and hypertrophy. It is not the cause of VI. The atria is still attached to the RV on the top, right.

Cause and Prevention of AS

Slide 18

The primary cause of AS at low altitude is rapid growth because of its direct relationship to MR, oxygen requirement by the tissue and CO. Feed conversion is negatively related to AS at the same growth rate since improved feed conversion requires less oxygen. Broilers should be selected for less oxygen requirement per gram of gain.

The larger bird in slide 18 is more apt to develop AS than the small broiler from the same flock. The fact that broilers stop growing when VI occurs, and that many broilers with ascites are smaller than their pen mates, who have continued to grow, may make this fact difficult to accept.

Slide 19

These four hearts, fixed and cut in cross-section, are from 12-wk-old roasters that were kept in an open shed and yard in October in Canada. Note marked RVH and dilation and hypertrophy of the right AV valve. The roasters continued to die from AS until they were processed at 16 wks. Cold is a common secondary cause of AS since cold increases MR and induces hemoconcentration. Up to 65% AS mortality has occurred in small farm flocks (50-1500 birds) of roasters that were kept in open sheds with night-time temperature dropping to 0°C. Broilers and roasters housed in open or plastic sided sheds may have 10 to 15% mortality from AS in the cold season.

Slide 20

Hypobaric chambers used to simulate high altitude. Vacuum pump between chambers.

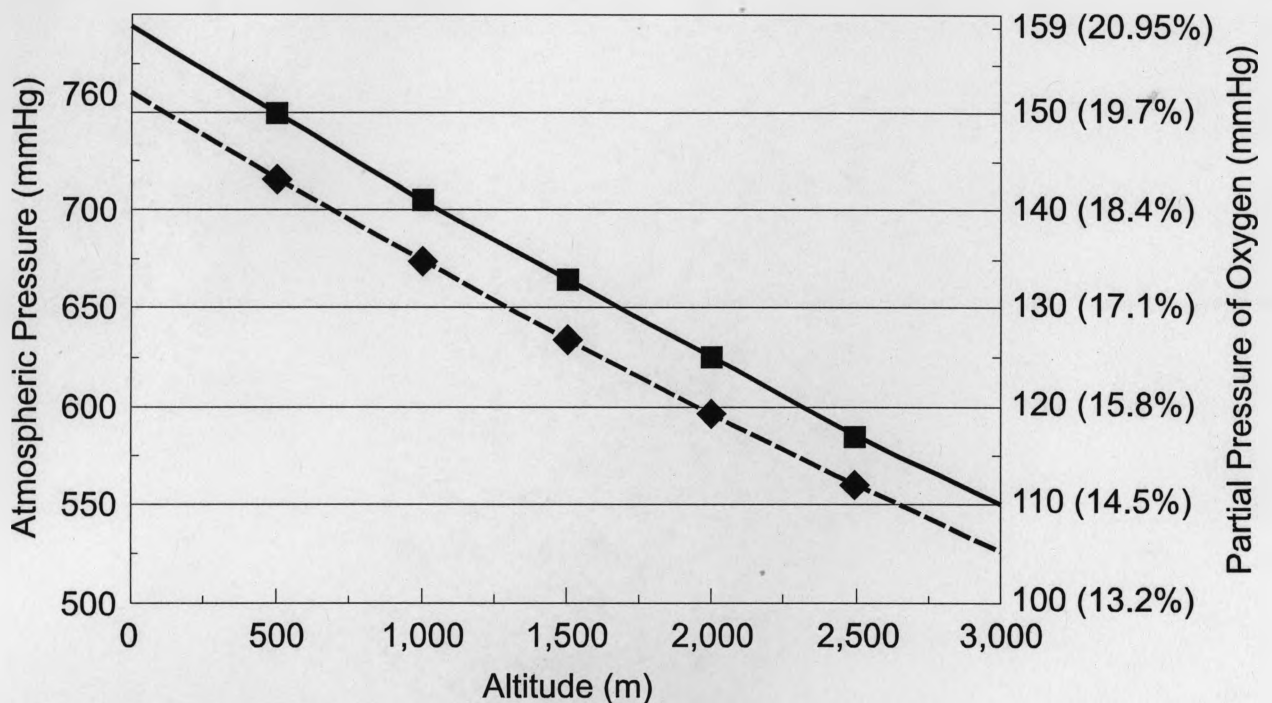


Fig. 2. With increasing altitude above sea level (0 to 3,000 m, on bottom) atmospheric pressure, scale on left (broken line), reduces from 760 mmHg at sea level to 525 mmHg at 3,000 m. Partial pressure of oxygen, scale on right (solid line), reduces from 159 mmHg at sea level to 110 mmHg at 3,000 m. The % oxygen, equivalent to the effect of that reduced pressure on oxygen transfer to Hb in the lung, is shown in brackets on the right.

Hypoxia is a major secondary cause of AS at moderate (above 750 m) and high altitude, but it too can be reduced by slowing MR. At high altitude low temperature at night is also a major contributing factor. Hypoxia results in hypoxemia stimulating polycythemia and increasing blood viscosity causing an increased resistance to flow (1,8,23). Transition metals (e.g. Co, Ni, Mn) increase the PCV, probably by stimulating erythropoiesis, and increase the incidence of ascites experimental (4,18). A high Hb or PCV for any reason will increase resistance to blood flow in the lung and some strains of chickens may have a higher PCV than others. VI and RVF also cause very marked hypoxemia and a rapid rise in the PCV. A high PCV may be the result of PH as well as a cause (12).

Air is 20.9% O₂. With increasing altitude the partial pressure of oxygen drops from 159 to 125 mmHg at 2000 m equal to what can be picked up by Hb at 16% oxygen (Figure 2). Leghorn chickens can fully oxygenate their Hb down to about 16% O₂, depending on O₂ demand, transit time, Hb-O₂ affinity etc. Some domestic ducks do not become hypoxemic even at 12% O₂ and wild waterfowl are even more resistant to hypoxia. Rapidly growing broiler chickens may not be able to fully oxygenate their Hb even at 20% O₂ (12).

Hypoxia may be induced by severe rickets and by reducing O₂ with CO₂ or inert gases in poultry sheds or experimentally. Respiratory disease or even pressure of abdominal contents on air sacs may also induce hypoxia. Intermittently hypoxia will cause polycythemia and AS (7,13).

Slide 21 Histologic section of broiler lung from broiler grown in hypobaric chamber at a simulated altitude of 2050 m (x500) Masson trichrome stain). Hypoxia may cause contraction of muscularized vessels in the lung and/or cause remodelling of terminal arteriols. This would increase resistance to blood flow in the lung and increase PH (23,26). No evidence of remodelling was seen in this experiment, but there is experimental evidence of hypoxic vasoconstriction in broilers (24,27).

Slide 22 A variety of nutrients (e.g. meat meal) and chemicals (e.g. chlorophenols and nitrophenols that uncouple oxydative phosphorylation) increase MR and O₂ consumption (3,8). In this feeding trial with chicken by-product there was a marked increase in AS (15).

Slide 23 Broiler chickens on 0.5% NaCl in the drinking water from day 7. The two broilers on the left died from AS at day 17. The control broiler on the right died from SDS.

AS caused by high Na⁺ is more prominent in young broilers and may affect females as frequently males. Moderate levels of Na⁺ may induce AS in several ways (14,21). High levels may cause diarrhea, dehydration and high mortality.

Slide 24 Broiler chick with ascites and subcutaneous edema caused by moderate (0.5%) Na⁺ in the drinking water.

Slide 25 Prominent testicular edema in three broiler chicks on moderate (0.5%) Na⁺ from NaHCO₃ in the drinking water. Kidney swelling and nephrosis may also be seen in sodium toxicity.

Slide 26 Fixed lungs from 4-week-old broiler chickens that died from AS induced by lung damage caused by aspergillosis. Gross lung and air sac damage may be mild. These lungs show very small focal granulomas (yellow dots) and areas of consolidation.

Ascites secondary to aspergillosis may follow a severe aspergillosis outbreak in young broilers that had high mortality from brooder pneumonia or it may occur 2 to 4 weeks after mild aspergillosis infection in which there was little loss from respiratory disease. Broilers that develop ascites following aspergillosis may be stunted rather than growing rapidly (11).

Slide 27 Histologic section of lung from broiler that died from AS following lung damage from aspergillosis infection (H&E x100). The blood capillaries in the lung of birds are present at hatch, but the air capillaries only develop as required. The parabronchiolar lobule on the right has been damaged by the aspergillosis infection and the openings from the atria to the air capillaries are closed. The air capillaries have not developed. There is milder damage in the lobules on the left.

Aspergillosis lung damage can result in AS by two mechanisms. 1. Hypoxia causes hypoxemia, with polycythemia increasing blood viscosity 2. Inflammation and fibrosis restrict blood flow through the lung. Both mechanisms increase resistance to bloodflow. Fibrosis of the lung is the main cause of PH in people. Although milder forms of lung damage may cause AS, pneumonia usually slows growth so that AS does not usually follow lung and air sac damage resulting from CRD, air sacculitis or pneumonia.

Slide 28 Histologic section of lung from broiler that died from AS syndrome following lung damage from high calcium and high vit D₃ top-dressed on the feed. (H&E x50). Lung damage resulted in hypoxia.

Slide 29 Prevention of AS usually involves some form of feed restriction by light-dark programs, skip-a-day, reduced quantity per day, reduced density (mash), reduced protein etc. Feed restriction may improve feed efficiency, but might increase days-to-market. Nipple drinkers may slow growth slightly and reduce AS. Avoiding hypoxic conditions, cold temperature and nutrients that increase BMR are also important.

CONCLUSION

The high oxygen requirement to sustain rapid growth is the primary cause of pulmonary hypertension-induced ascites in meat-type chickens. There are a variety of additional or secondary causes that can increase or trigger the ascites syndrome. The additive factors may cause increased blood flow because of a higher metabolic rate (cold, heat, certain nutrients, chemicals, etc) or greater resistance to flow as a result of increased blood viscosity or red blood cell rigidity or reduced vascular capacity in the lung. Some additive factors may cause both increased flow and resistance to flow. The primary genetic cause is the heritability of the blood and high oxygen requirement and the resistance to flow.

1. Burton, R.R. and A.F. 1987. Ascites in the chicken. *Avian Dis.* 31: 658-661.
2. Cueva, S., H. Sillau, 1987. Hypertension and right ventricular hypertrophy in meat-type chickens. *Avian Dis.* 31: 658-661.
3. Decupéré, E., C. Vegh. 1987. Sensitivity to triiodothyronine in meat-type chickens with a high susceptibility for ascites. *Br. Poult. Sci.* 35: 287-298.
4. Diaz, G.J., R.J. Julian and E.J. Squires. 1994. Cobalt-induced polycythaemia causing right ventricular hypertrophy and ascites in meat-type chickens. *Avian Pathol.* 23: 91-104.
5. Hernandez, A. 1987 Hypoxic ascites in broilers: a review of several studies done in Colombia. *Avian Dis.* 31: 658-661.

Slide 29
 This slide could
 be take out of
 pics from other MS
 are not appropriate.
 replace with a pic of
 poultry sheds at
 high altitude

Aspergillosis lung damage can result in AS by two mechanisms. 1. Hypoxia causes hypoxemia, with polycythemia increasing blood viscosity 2. Inflammation and fibrosis restrict blood flow through the lung. Both mechanisms increase resistance to bloodflow. Fibrosis of the lung is the main cause of PH in people. Although milder forms of lung damage may cause AS, pneumonia usually slows growth so that AS does not usually follow lung and air sac damage resulting from CRD, air sacculitis or pneumonia.

Slide 28 Histologic section of lung from broiler that died from AS syndrome following lung damage from high calcium and high vit D₃ top-dressed on the feed. (H&E x50). Lung damage resulted in hypoxia.

Slide 29 Prevention of AS usually involves some form of feed restriction by light-dark programs, skip-a-day, reduced quantity per day, reduced density (mash), reduced protein etc. Feed restriction may improve feed efficiency, but might increase days-to-market. Nipple drinkers may slow growth slightly and reduce AS. Avoiding hypoxic conditions, cold temperature and nutrients that increase BMR are also important.

CONCLUSION

The high oxygen requirement to sustain rapid growth is the primary cause of pulmonary hypertension-induced ascites in meat-type chickens. There are a variety of additional or secondary causes that can increase or trigger the ascites syndrome. The additive factors may cause increased blood flow because of a higher metabolic rate (cold, heat, certain nutrients, chemicals, etc) or greater resistance to flow as a result of increased blood viscosity or red blood cell rigidity or reduced vascular capacity in the lung. Some additive factors such as high sodium may cause both increased flow and increased resistance to flow. Reducing the ascites syndrome must address the primary genetic cause of insufficient vascular capacity in the lung, reduced oxygen-carrying ability of the blood and high oxygen requirement and the secondary factors that increase flow and resistance to flow.

REFERENCES

1. Burton, R.R. and A.H. Smith. 1967. The effect of polycythemia and chronic hypoxia on heart mass in the chicken. *J. Appl. Physiol.* 22: 782-785.
2. Cueva, S., H. Sillau, A. Valenzuela and H. Ploog. 1974. High altitude induce pulmonary hypertension and right heart failure in broiler chickens. *Res. Vet. Sc.* 16: 370-374.
3. Decupéré, E., C. Vega, T. Bartha, J. Buyuse, J. Zoons and G.A.A. Albers. 1994. Increased sensitivity to triiodothyronine (T₃) of broiler lines with a high susceptibility for ascites. *Br. Poult. Sci.* 35: 287-298.
4. Diaz, G.J., R.J. Julian and E.J. Squires. 1994. Cobalt-induced polycythaemia causing right ventricular hypertrophy and ascites in meat-type chickens. *Avian Pathol.* 23: 91-104.
5. Hernandez, A. 1987 Hypoxic ascites in broilers: a review of several studies done in Colombia. *Avian Dis.* 31: 658-661.

6. Huchzermeyer F.W. and A.M.C. De Ruyck. 1986. Pulmonary hypertension syndrome associated with ascites in broilers. *Vet. Rec.* 119: 94.
7. Julian, R.J. 1987. The effect of increased sodium in the drinking water on right ventricular hypertrophy, right ventricular failure and ascites in broiler chickens. *Avian Pathol.* 16: 71-71.
8. Julian, R.J. 1993. Ascites in poultry. Review. *Avian Pathol.* 22: 419-454.
9. Julian, R.J. 1996. Cardiovascular disease. In: *Poultry Diseases*, 4th Ed. F.T.W. Jordan and M. Pattison, (eds). London, Baillière Tindall, pp. 343-374.
10. Julian, R.J. 1996. The cardiovascular system. In: *Avian Histopathology*, 2nd ed. C. Riddell, ed. Am. Assoc. Avian Pathologists, Kennett Square, Pennsylvania, pp. 69-88.
11. Julian, R.J. and M. Goryo. 1990. Pulmonary aspergillosis causing right ventricular failure and ascites in meat-type chickens. *Avian Pathol.* 19: 643-654.
12. Julian, R.J. and S.M. Mirsalimi. 1992. Blood oxygen concentration of fast-growing and slow-growing broiler chickens, and chickens with ascites from right ventricular failure. *Avian Dis.* 36: 730-732.
13. Julian, R.J. and E.J. Squires. 1994. Haematopoietic and right ventricular response to intermittent hypobaric hypoxia in meat-type chickens. *Avian Path.* 23: 539-545.
14. Julian R.J., L.J. Caston, and S. Leeson. 1992. The effect of dietary sodium on right ventricular failure-induced ascites, gain and fat deposition in meat-type chickens. *Can. J. Vet. Res.* 56: 214-219.
15. Julian R.J., L.J. Caston, S.M. Mirsalimi and S. Leeson. 1992. Effect of poultry by-produce meal on pulmonary hypertension, right ventricular failure and ascites in broiler chickens. *Can. Vet. J.* 33: 382-385.
16. López-Coello, C. 1985. Recent investigations on ascites in Mexico. *Proc. 34th Western Poultry Disease Conference*. Davis, California, pp. 71-73.
17. López-Coello, C., L. Paasch, R. Rosiles and C. Casas. 1982. Ascites in broilers due to undetermined causes. *Proc. 31st Western Poultry Disease Conference and 15th Poultry Health Symposia*, Davis, California. Pp. 13-15.
18. Martinez, D.A. and G.J. Diaz. 1996. Effect of graded levels of dietary nickel and manganese on blood haemoglobin content and pulmonary hypertension in broiler chickens. *Avian Pathol.* 25: 537-549.
19. Maxwell M.H., S. Spence, G.W. Robertson and M.A. Mitchell. 1990. Haematological and morphological responses of broiler chicks to hypoxia. *Avian Pathol* 19: 23-40.
20. Mirsalimi, S.M. and R.J. Julian. 1991. Reduced erythrocyte deformability as a possible contributing factor to pulmonary hypertension and ascites in broiler chickens. *Avian Dis.* 35: 374-379.
21. Mirsalimi, S.M., P.J. O'Brien and R.J. Julian. 1992. Changes in erythrocyte deformability in NaCl-induced right-sided cardiac failure in broiler chickens. *Am. J. Vet. Res.* 53: 2359-2363.
22. Mirsalimi, S.M., R.J. Julian and E.J. Squires. 1993. Effect of hypobaric hypoxia on slow- and fast-growing chickens fed diets with high and low protein levels. *Avian Dis.* 37: 660-667.
23. Monge C. and F. León-Velarde. 1991. Physiological adaptation to high altitude: oxygen transport in mammals and birds. *Physiol. Rev.* 71: 1135-1171.
24. Owen, R.L., R.F. Wideman, Jr., and B.S. Cowan. 1995. Changes in pulmonary arterial and femoral arterial blood pressure upon acute exposure to hypobaric hypoxia in broiler chickens. *Poult. Sci.* 74: 708-715.
25. Powell, F.L., R.H. Hastings, and R.W. Mazzone. 1985. Pulmonary vascular resistance during unilateral pulmonary arterial occlusion in ducks. *Am. J. Physiol.* 249: R39-R43.

26. Reid, L.M, 1986. Structure and function in pulmonary hypertension. New perceptions. Chest 89: 279-288.
27. Wideman, R.F. Jr., and Y.K. Kirby. 1995. A pulmonary artery clamp model for inducing pulmonary hypertension syndrome (ascites) in broilers. Poult. Sci. 74: 805-812.
28. Wilson J.B., R.J. Julian and I.K. Barker. 1988. Lesions of right heart failure and ascites in broiler chickens. Avian Dis. 32: 246-261.